

FELINE INJECTION-SITE SARCOMA

ABCD guidelines on prevention and management



Katrin Hartmann, Michael J Day*, Etienne Thiry, Albert Lloret, Tadeusz Frymus, Diane Addie, Corine Boucraut-Baralon, Herman Egberink, Tim Gruffydd-Jones, Marian C Horzinek, Margaret J Hosie, Hans Lutz, Fulvio Marsilio, Maria Grazia Pennisi, Alan D Radford, Uwe Truyen and Karin Möstl

Overview: In cats, the most serious of adverse effects following vaccination is the occurrence of invasive sarcomas (mostly fibrosarcomas): so-called ‘feline injection-site sarcomas’ (FISSs). These develop at sites of previous vaccination or injection. They have characteristics that are distinct from those of fibrosarcomas in other areas and behave more aggressively. The rate of metastasis ranges from 10–28%.

Pathogenesis: The pathogenesis of these sarcomas is not yet definitively explained. However, chronic inflammatory reactions are considered the trigger for subsequent malignant transformation. Injections of long-acting drugs (such as glucocorticoids, and others) have been associated with sarcoma formation. Adjuvanted vaccines induce intense local inflammation and seem therefore to be particularly linked to the development of FISS. The risk is lower for modified-live and recombinant vaccines, but no vaccine is risk-free.

Treatment and prevention: Aggressive, radical excision is required to avoid tumour recurrence. The prognosis improves if additional radiotherapy and/or immunotherapy (such as recombinant feline IL-2) are used. For prevention, administration of any irritating substance should be avoided. Vaccination should be performed as often as necessary, but as infrequently as possible. Non-adjuvanted, modified-live or recombinant vaccines should be selected in preference to adjuvanted vaccines. Injections should be given at sites at which surgery would likely lead to a complete cure; the interscapular region should generally be avoided. Post-vaccination monitoring should be performed.

*The ABCD is grateful to Professor Michael Day, of the School of Veterinary Sciences, University of Bristol, UK, who, though not a member of the Board, contributed to this article.

Introduction

Recently, vaccination of cats has received scientific and public attention linked to the supposition that a range of rare adverse effects can arise following vaccination. In cats, the most serious of these adverse consequences is the occurrence of invasive sarcomas (mostly fibrosarcomas), so-called ‘feline injection-site sarcomas’ (FISSs), that can develop within the skin at sites of previous vaccination. Despite extensive research on the pathogenesis of these sarcomas, there is no definitive causal relationship that explains their occurrence and the direct link to vaccination. The most accepted hypothesis suggests that a chronic inflammatory reaction at the site of injection provides a trigger for subsequent malignant transformation.

Epidemiology and characterisation

In 1991, an increased incidence of tumours in cats that developed at injection sites was first reported in the United States.¹ This observation was connected to an increased use of rabies and feline leukaemia virus (FeLV) vaccinations.^{2,3} As a consequence, these tumours were first called feline ‘vaccine-associated sarcomas’. However, the subsequent finding that other, non-vaccinal injectables can also cause this type of tumour has led to reclassification of these neoplasms as ‘feline injection-site sarcomas’ (FISSs). These tumours seem to be unique to cats,⁴ although comparable tumours have been reported in ferrets⁵ and very occasionally in dogs.⁶

FISSs occur at sites typically used for vaccination and injections, such as the interscapular region (Figure 1), the lateral thoracic or abdominal wall, the lumbar region, and the area of the semimembranosus and semitendinosus muscles. FISSs are most commonly located in the subcutis, but also can occur intramuscularly.^{7,8}

FISSs can occur as early as 4 months and up to 3 years after an injection. They are characterised by invasive local growth in the subcutis, often with spread along fascial planes.⁹ Most FISSs are fibrosarcomas,¹⁰ but other malignancies, such as osteosarcomas,¹¹ chondrosarcomas,⁷



European Advisory Board on Cat Diseases
www.abcdcatsvets.org
www.abcd-vets.org

Corresponding author: Katrin Hartmann
Email: Hartmann@medizinische-kleintierklinik.de



rhabdomyosarcomas,⁷ malignant fibrous histiocytomas,^{7,11} and myofibroblastic sarcomas⁸ have also been described.

FISSs have histological characteristics that are distinct from those of fibrosarcomas in other areas. Typically there is perivascular infiltration of lymphocytes and macrophages at the tumour periphery, a central area of necrosis, inflammation and local infiltration of tumour cells (Figure 2).^{10,12} FISSs behave more aggressively than sarcomas at other sites.¹³ The rate of metastasis ranges from 10–28%.^{14,15} The lung is the most common site of metastasis, followed by regional lymph nodes and abdominal organs, such as the kidney, spleen, intestine and liver.^{16,17}

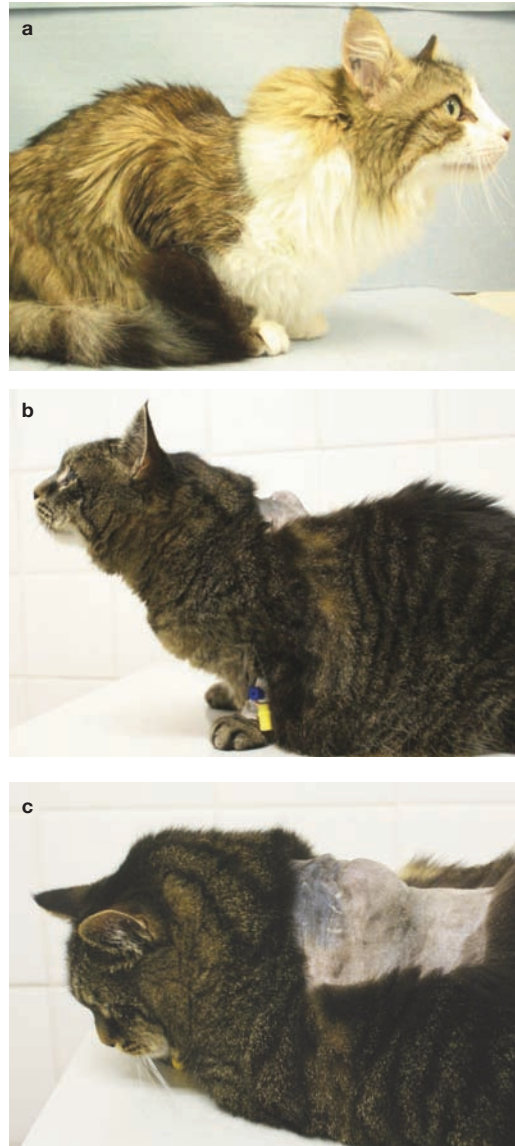
In the past 20 years, an epidemiological association has been demonstrated between vaccination and the later development of FISS.^{3,13,18–21} The incidence of FISS has been estimated at 1–4 in every 10,000 vaccinated cats in the USA,^{22,23} and the ratio of injection-site to non-injection-site sarcomas increased from 0.5 in 1989 to 4.3 in 1994.¹⁰ In one study in the USA, reported rates of reaction were 0.3 FISSs per 10,000 vaccinations and 11.8 postvaccinal inflammatory reactions per 10,000 vaccinations in cats.²² If inflammatory reactions are a necessary prelude to FISS, then these rates suggest that 1 in 35–40 inflammatory reactions develop into FISS. In the UK, the incidence of FISSs seems to be relatively low (incidence risk of FISS per year was estimated to be 1 per 16,000–50,000 cats registered by practices, 1 per 10,000–20,000 cat consultations, and 1 per 5000–12,500 vaccination visits).²⁴ One reason for the low rate might be that rabies vaccination is not a routine procedure for cats in the UK. One study in Canada investigated the annual prevalence of feline postvaccinal sarcomas among 11,609 feline skin mass submissions from 1992 to 2010 and revealed no decrease in disease prevalence or increase in age of affected cats in response to change in vaccination formulation or recommended changes in feline vaccination protocols.²⁵

Pathogenesis

Despite extensive research, there is no definitive proof of the pathogenesis of FISS. The most widely accepted hypothesis suggests that a chronic inflammatory

FISSs are usually firm, indolent, seemingly well-circumscribed, subcutaneous masses that are often not freely moveable.

Figure 1 (a–c) Cats with feline injection-site sarcoma. Courtesy of Johannes Hirschberger, Ludwig Maximilians University, Munich, Germany



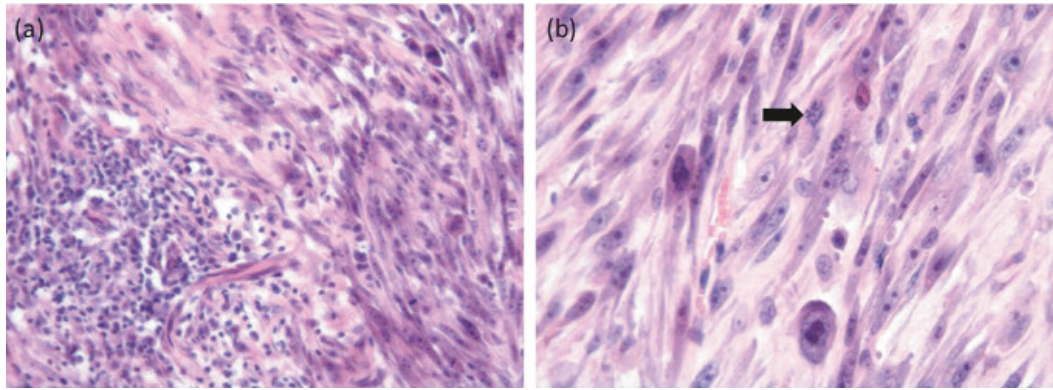
reaction at the site of an injection acts as a trigger for subsequent malignant transformation. Adjuvanted vaccines seem to be particularly linked to the development of FISS due to the more intense local inflammation associated with such products. This idea is supported by frequent identification of adjuvants in histological or ultrastructural investigations of these sarcomas.^{12,18}

Many data suggest an association between vaccination and FISS in cats. Aluminium, a vaccine adjuvant, has been found in biopsy samples of FISS.²⁶ In most inactivated vaccines, an adjuvant is added to enhance the inflammation at the site of injection, which is intended and necessary when applying a killed agent in order to trigger the necessary immune response. However, this inflammation might potentially lead to malignant transformation. Traces of adjuvants can be seen in the inflammatory reaction, specifically accumulated within macrophages or multinucleate giant

cells, and later in histological sections of FISS in the transformed fibroblast.¹⁸ Intracellular crystalline particulate material was found in an ultrastructural study in 5 of 20 FISSs investigated, and in one of the five cases was identified as aluminium-based.¹² Although no specific vaccine or adjuvant has been incriminated,²⁷ local irritation from adjuvant is thought to stimulate mainly fibroblasts to the point that malignant transformation occurs.

At first, only rabies and FeLV vaccines were identified as risk factors,^{3,13,23} but subsequently other vaccines, including vaccines against feline panleukopenia virus (FPV), feline herpesvirus-1 (FHV-1) and feline calicivirus (FCV), were also found to be involved in the development of FISS in some cases.^{13,23,28–30} In addition to vaccines, injections such as long-acting glucocorticoids, penicillin, lufenuron,^{27,31,32} cisplatin³³ and meloxicam³⁴ have been associated with sarcoma formation. One study found that the frequency of administration of long-acting glucocorticoid injections (dexamethasone, methylprednisolone and triamcinolone) was significantly higher in cats with FISS in the interscapular region than in control cats.³⁵ Fibrosarcomas were also reported at the site of

Figure 2 Histological sections of a 2 cm diameter mass removed from the lateral thorax of a 13-year-old domestic shorthair cat. A similar interscapular mass had been removed from this cat 2 months previously. (a) A focus of lymphoplasmacytic inflammation is contained within the surrounding sarcoma. (b) Higher magnification of the neoplastic tissue reveals a pleomorphic population of neoplastic spindle cells with occasional giant nuclei and irregular mitotic activity (arrow). Haematoxylin and eosin stain. Courtesy of Michael Day, School of Veterinary Sciences, University of Bristol, UK



a deep, non-absorbable suture in one cat;³⁶ around a surgical swab in the abdomen of one cat;³⁷ adjacent to the site of microchip implantation in two cats;^{38,39} and associated with a subcutaneous fluid port device.^{38,39} This suggests that all inflammatory reactions, theoretically, have the potential to lead to the development of FISS by triggering uncontrolled proliferation of fibroblasts and myofibroblasts, which, in some cases, results in malignant transformation.

Although many causes of inflammation are associated with FISS development, the risk seems to be higher for vaccines compared with other injections; among vaccines, the risk seems to be higher when adjuvanted vaccines are used. Srivastav et al³⁵ compared associations between vaccine types and other injectable drugs with the development of FISS in a case-control study of 181 cats with soft tissue sarcomas (cases), 96 cats with tumours at non-vaccine regions (control group 1), and 159 cats with basal cell tumours (control group 2). There was a significant association between the administration of various types of vaccines and other injectable products (eg, long-acting corticosteroids) and FISS development. Of 192 cats with sarcoma, 101 had vaccinations at the site of tumour development during the preceding 3 years, and 23 had received other injections.³⁵ This study also showed that adjuvanted inactivated vaccines were significantly more commonly associated with FISS development than other vaccines; of 35 vaccinated cats with sarcoma on the hindlimb, 25 cats had received adjuvanted vaccines, seven cats had received modified-live virus (MLV) vaccines (FPV, FHV-1 and FCV), and only one cat had received a recombinant vaccine. These findings also indicated that no vaccines are risk-free.³⁵

The mechanism by which the inflammatory reaction causes tumour formation is not fully understood. Growth factors promote proliferation, can induce malignant transformation, and also can be involved in the regulation of

angiogenesis. Overexpression of growth factors and oncogene activation have been demonstrated in cats with FISS and are suspected to play a role in tumour development.^{40–42}

As vaccination against FeLV is associated with a higher risk of FISS, some studies looked at a possible role of FeLV and its mutant feline sarcoma virus (FeSV) in the development of FISS, but could not detect either FeLV or FeSV in the tumours.⁴³ Furthermore, no other viruses, including feline immunodeficiency virus, feline foamy virus, polyomaviruses or papillomaviruses were detected in tumour tissues.^{44–47} No evidence has been found to implicate replication or expression of endogenous retroviruses in FISS formation.^{45,46}

The observation that not all cats develop FISS after vaccination suggests that there might be a genetic predisposition. It has been suggested that there is a higher incidence of FISS in siblings of affected cats, and that some cats tend to develop more than one FISS. Alterations with unknown relevance such as hyperploidy,⁴⁸ translocations⁴⁹ and triploidy⁵⁰ of oncogene and tumour suppressor loci have been found on extra chromosomes and monosomic chromosomes in affected cats. Mutations have been identified in the tumour suppressor gene p53, which is implicated in cancer initiation and progression in sarcoma tissue of cats with FISS.^{51–55} A case-control study (50 domestic shorthair cats with a confirmed diagnosis of FISS and 100 disease-free matched controls) investigating a possible association between polymorphisms in the genomic sequence of the feline p53 gene and a predisposition to FISS, found a strong association between FISS and the presence of specific nucleotides at two of the polymorphic sites.⁵⁶ However, another study, conducted in Munich, Germany, could not reproduce these findings and observed no association with the polymorphisms described.⁵⁷

European Advisory Board on Cat Diseases

The European Advisory Board on Cat Diseases (ABCD) is a body of experts in immunology, vaccinology and clinical feline medicine that issues guidelines on prevention and management of feline infectious diseases in Europe, for the benefit of the health and welfare of cats. The guidelines are based on current scientific knowledge of the diseases and available vaccines concerned.

The latest version of the guidance provided in this article is available at www.abcdcatsvets.org and www.abcd-vets.org

Management

Appropriate treatment should first include staging and careful planning of the surgery, because aggressive, radical excision is crucial to avoid tumour recurrence. The prognosis improves if, in addition to radical surgery, adjunctive treatments such as radiotherapy or immunotherapy are used. Preoperatively, (contrast-enhanced) computed tomography (CT) or magnetic resonance imaging (MRI) should be obtained for staging, and to determine the extent of the tumour and the size of the radiation field required to maximise the chance of a successful outcome.⁵⁸ It was shown that the actual size of tumours determined by CT could be twice that estimated at physical examination.^{59,60} Surgeons should attempt to achieve complete, en bloc, surgical tumour resection with at least 3 cm (ideally, 5 cm) margins⁶¹ [EBM grade III] and the removal of one fascial plane underlying the tumour, because incomplete resection can result in recurrence as early as 2 weeks after surgery [EBM grade III].^{28,62} Treatment using surgical excision alone has a recurrence rate of up to 70%, with tumour regrowth usually occurring in the first 6 months after surgery [EBM grade III].¹³ Tumour-free margins are very important for a longer disease-free interval, which was 700 days when complete tumour excision was accomplished, but only 112 days for incomplete resection [EBM grade III].⁶³ However, even with clean surgical margins, the recurrence rate can be as high as 50% [EBM grade III].⁶⁴

Preoperative or postoperative radiation therapy significantly decreases recurrence rates and prolongs remission times,^{16,63,65} while the benefit of chemotherapy is not proven as large prospective randomised controlled trials are lacking. One non-randomised study found no significant difference between control cats (surgery alone) and cats treated with surgery and doxorubicin [EBM grade III],⁶⁶ while a recent study demonstrated chemotherapy benefits compared with historical controls using a combination of neoadjuvant and adjuvant chemotherapy (three epirubicin doses before and after surgery) [EBM grade III].⁶⁷ Chemotherapy mainly remains an option for palliative treatment in cats with non-resectable FISS, when radiation therapy is not available.

Additional immunotherapy appears to be promising.^{68–70} Results of prospective randomised controlled studies of cytokine gene transfer techniques for adjuvant-immunological treatment of FISS showed reduced recurrence rates. In cats receiving gene therapy by the peritumoural administration of histoincompatible Vero cells expressing human interleukin-2 (hIL-2) in addition to surgery and

EBM grades

The ranking system for grading the level of evidence of various statements within the management and prevention sections of this article is described on page 574 of this Special Issue.

radiation therapy, only 5/16 (31%) had FISS recurrence, while 11/16 control cats (69%) that had surgery and radiation therapy, but no immunotherapy, had FISS recurrence within 16 months [EBM grade I].⁷¹ Use of neoadjuvant gene therapy using a non-viral vector that expresses feline granulocyte-macrophage colony-stimulating factor (GM-CSF) or a combination of the feline genes GM-CSF, interleukin (IL)-2 and interferon- γ (IFN- γ) was well tolerated by cats [EBM grade I]^{68,69} and showed promising results. Recombinant feline IL-2 is now commercially available in Europe for the treatment of FISS in combination with surgical excision and radiation therapy. In a randomised controlled clinical trial, administration of a recombinant canarypox virus expressing feline IL-2 was well tolerated and resulted in a significantly longer median time to relapse and a significant reduction in the risk of relapse at 1 year and 2 years [EBM grade I].⁷⁰

Prevention

Prevention consists of three general considerations:

Key considerations in the prevention of FISS

- ✦ Injections in cats should always be given at sites at which surgery (such as amputation of a limb or excision of lateral abdominal skin) would likely lead to a complete cure with the least complicated surgical procedure
- ✦ General recommendations to reduce the inflammatory reaction at injection sites should be followed, such as avoiding the administration of irritating substances
- ✦ It is advised to vaccinate only as often as necessary and as infrequently as possible (eg, according to the principles of current vaccination guidelines, avoiding FeLV vaccination in FeLV antigen-positive, FeLV PCR-positive or FeLV antibody-positive cats)

Choice of injection site

In general, injecting distally in a leg aids, where necessary, in the subsequent treatment of sarcoma by amputation of the leg (because these tumours are very difficult to excise completely and often recur after resection).²⁰ Administration of vaccines (or other injections) between the scapulae is generally contraindicated because tumour resection is almost impossible in this location.

To assess the acceptance of the recommendations of the Vaccine-Associated Feline Sarcoma Task Force (VAFSTF), published in 1996, a study involving 392 cats with FISSs compared the anatomical locations of tumours between cases with FISS diagnosed before and after publication of these recommendations.⁷² The proportions of FISS significantly decreased in the interscapular (53% to 40%) and right and left thoracic (10% to 4% and 9% to 1%, respectively) regions, whereas

the proportions of FISS significantly increased in the right thoracic limb (1% to 10%) and the combined regions of the right pelvic limb with the right lateral aspect of the abdomen (13% to 25%) and the left pelvic limb with the left lateral aspect of the abdomen (11% to 14%). Thus, while veterinarians are complying with vaccination recommendations to some extent, a high proportion of tumours still developed in the interscapular region. There was also an increase in lateral abdominal FISSs, which could be attributable to aberrant placement of injections intended for the pelvic limbs. It remains the case that only administration of vaccines as distally as possible on a limb allows for complete surgical margins if limb amputation is required [EBM grade III].⁷³ Current data in Europe shows a similar situation. In a study examining the location of FISSs in cats presented to the oncology service at the University teaching hospital in Munich, most still occurred between the scapulae (40%), followed by the right (19%) and left thoracic walls (13%).⁷⁴

Unfortunately, there is still insufficient clinical information to enable evidence-based vaccine site recommendations. The majority of safety and efficacy data comes from licensing studies in which vaccines are administered subcutaneously in the interscapular region (which should not be used for any injection in the clinical setting). Current research indicates that radical surgical resection of injection-site sarcomas including margins of at least 3 cm, but preferably 5 cm [EBM grade III],⁶¹ is associated with the highest response rate and long-term survival [EBM grade III].¹⁵ With this in mind, the Feline Vaccination Advisory Panel of the American Association of Feline Practitioners (AAFP) conducted an informal survey of veterinarians whose practices focused on radiation (12), surgical (36), and medical (44) oncology for opinions on what the preferred vaccination sites should be.⁶² These experts agreed that distal to the stifle, followed by distal to the elbow, were their preferred sites. Nearly as popular was the tail. Respondents frequently commented that vaccines should be administered as low on the leg as possible. They added that vaccination of cats resting in a crouched position often resulted in inadvertent injection of the skin fold of the flank, leading to tumours that were difficult to resect.⁶² This is reflected in a recent paper that found an increase in lateral abdominal injection-site sarcomas since the publication of the VAFSTF's vaccination recommendations in 1996.⁶¹

Based on these expert opinions, the AAFP now recommends in its new guidelines,⁶² consistent with the earlier (2006) guidelines,⁷⁵ that vaccines against FPV, FHV-1 and FCV should be administered below the right elbow; FeLV vaccines should be administered below the

Although many causes of inflammation are associated with FISS development, the risk seems to be higher for vaccines (particularly adjuvanted vaccines) compared with other injections.



left stifle; and rabies vaccines should be administered below the right stifle.⁶² So far, vaccination in the tail has not been considered a practical option. However, a recent pilot study demonstrated that vaccination in the tail was well tolerated and that tail-vaccinated cats developed an antibody response comparable to that observed following injection of the vaccine distally in the leg [EBM grade II].⁷⁶ Further studies are warranted to confirm whether this would be an alternative option leading to equal protection rates.

Alternative recommendations are made by the Vaccination Guidelines Group (VGG) of the World Small Animal Veterinary Association, which recognises the practical difficulties often faced by veterinarians attempting vaccination into limbs or the tail. The advice of the VGG is that a preferred site for vaccine delivery (and surgical resection of a FISS that might arise) is the skin over the lateral abdomen. This is a procedure that appears well tolerated in the majority of cats.

As a general recommendation, recording the sites of injections in the patient's medical records is important. In addition, post-vaccination monitoring plays a vital role (see box).

Recommendations for reducing inflammatory reactions

In terms of preventing inflammatory reactions at injection sites, there are a few recommendations to follow. Cats should receive as few subcutaneous injections as possible. Intramuscular injections in cats should be avoided because intramuscular tumours develop with a similar frequency, but are more difficult to detect early. Whenever feasible, cats should receive drugs orally or intravenously. The subcutaneous injection of long-acting irritating substances (such as long-acting glucocorticoids) should be avoided.

One study examined potential risk factors when administering vaccines²⁷ and few factors

Post-vaccination monitoring

Veterinarians should instruct their clients to monitor vaccination (and other injection) sites for swelling or lumps in order to detect potential sarcomas early and at a time when they still can be removed successfully.

Practitioners and owners should follow the '3-2-1' rule.

Incisional wedge biopsies or total removal and histological examination of any mass is warranted if the mass

is still present **3 months** after vaccination, if the mass becomes larger than **2 cm** in diameter, or is increasing in size **1 month** after vaccination.

Practitioners and owners should follow the '3-2-1' rule.

In general, a diagnostic work-up is warranted when any cutaneous mass is noted in a cat. FISSs are usually firm, indolent, seemingly well-circumscribed, subcutaneous masses that are often not freely moveable.

were associated with the development of FISS. It was observed that the size of the needle and the syringe, the velocity of injection, and whether manual pressure was applied after injection or not, played no role. In contrast, the temperature of the vaccine made a significant difference, with cold vaccines being associated with a higher risk of FISS development than vaccines at room temperature.²⁷ Thus, vaccines should be taken out of the refrigerator about 15 minutes before injection, but not much longer, to avoid reduction in vaccinal efficacy.

If available, intranasal or oral vaccines would be preferable over injectable vaccines in cats. However, in most countries only injectable vaccines are available. Therefore, vaccines are preferred that cause the least subcutaneous inflammatory reaction. Vaccines without adjuvants should be used rather than adjuvant-containing vaccines, which means that MLV or recombinant vaccines (eg, canarypox-vectored vaccine) without adjuvant are preferred over inactivated vaccines with adjuvants.

It has been shown that recombinant canarypox-vectored vaccines cause less inflammation at the injection site. This was demonstrated in rats,⁷⁷ and in a study in cats, in which the typical granulomatous inflammation did not develop at the injection site when using these particular vaccines.⁷⁸ An extensive study investigating the subcutaneous tissue response following administration of a single dose of multi-component vaccines confirmed these findings.⁷⁹ Three groups of 15 cats were injected with one of three vaccines or saline as a negative control; cats in group A received a non-adjuvanted recombinant canarypox-vectored FeLV vac-

Recording the sites of injections in the patient's medical records is important.



cine; cats in group B received an FeLV vaccine with a lipid-based adjuvant; and cats in group C were vaccinated with an FeLV vaccine adjuvanted with an alum-Quil A mixture. On days 7, 21 and 62 post-vaccination, significantly less inflammation was associated with administration of the non-adjuvanted recombinant canarypox-vectored vaccine. The inflammation was most severe in the cats receiving the aluminium-based adjuvant. Cats receiving adjuvanted vaccines had evidence of residual adjuvant material accumulated within macrophages even at 62 days post-vaccination.⁷⁹ In a case-control study investigating associations between vaccine types and development of FISS, adjuvanted inactivated vaccines were significantly more commonly associated with sarcoma development than other vaccines; of 35 vaccinated cats with sarcoma on the hindlimb, 25 cats had received adjuvanted vaccines, seven cats had received MLV vaccines (FPV, FHV-1 and FCV), while only one cat had received a recombinant canarypox-vectored vaccine [EBM grade III].³⁵

Vaccination schedules

Finally, to prevent development of FISS, cats should be vaccinated no more than necessary. Therefore, long vaccination intervals should be applied in adult animals; vaccines (such as rabies vaccines and FPV vaccines) that are licensed for 3 year or even 4 year boosters should be preferred; no FeLV or rabies vaccinations should be administered to indoor-only cats; and immune cats should not be vaccinated (eg, if antibodies are detected). This confirms the necessity of individual vaccination schedules.

KEY POINTS

- ❖ Vaccination of cats provides essential protection and should not be stopped because of the risk of feline injection-site sarcoma (FISS).
- ❖ Vaccines are not the only injectable medical products associated with FISS.
- ❖ An individual vaccination schedule is important. Cats should be vaccinated no more than necessary, in accordance with current guidelines.
- ❖ Appropriate sites for injection should be selected. The interscapular region should generally be avoided. Vaccines should be injected at a site from which a mass can easily be surgically removed, such as distally on a leg or in the skin of the lateral abdomen.
- ❖ Vaccines should be brought to room temperature prior to administration, but should not be kept unrefrigerated for hours.
- ❖ Whenever possible, subcutaneous, rather than intramuscular, injection should be performed.
- ❖ The preference is for: non-adjuvanted vaccines over those containing adjuvant; modified-live vaccines or recombinant vaccines over inactivated vaccines; and vaccines with a long duration of immunity.
- ❖ Post-vaccination monitoring should be performed. Any lump at the site of injection that is still present 3 months after vaccination, that is larger than 2 cm in diameter, or that it is increasing in size 1 month after vaccination should be surgically removed.

Funding

The authors received no specific grant from any funding agency in the public, commercial or not-for-profit sectors for the preparation of this article. The ABCD is supported by Merial, but is a scientifically independent body and its members receive no stipends from Merial.

Conflict of interest

The authors do not have any potential conflicts of interest to declare.

References

- 1 Hendrick MJ and Dunagan CA. **Focal necrotizing granulomatous panniculitis associated with subcutaneous injection of rabies vaccine in cats and dogs: 10 cases (1988–1989).** *J Am Vet Med Assoc* 1991; 198: 304–305.
- 2 Hendrick MJ and Goldschmidt MH. **Do injection site reactions induce fibrosarcomas in cats?** *J Am Vet Med Assoc* 1991; 199: 968.
- 3 Kass PH, Barnes WG, Jr, Spangler WL, et al. **Epidemiologic evidence for a causal relation between vaccination and fibrosarcoma tumorigenesis in cats.** *J Am Vet Med Assoc* 1993; 203: 396–405.
- 4 Carroll EE, Dubielzig RR and Schultz RD. **Cats differ from mink and ferrets in their response to commercial vaccines: a histologic comparison of early vaccine reactions.** *Vet Pathol* 2002; 39: 216–227.
- 5 Munday JS, Stedman NL and Richey LJ. **Histology and immunohistochemistry of seven ferret vaccination-site fibrosarcomas.** *Vet Pathol* 2003; 40: 288–293.
- 6 Vascellari M, Melchioti E, Bozza MA, et al. **Fibrosarcomas at presumed sites of injection in dogs: characteristics and comparison with non-vaccination site fibrosarcomas and feline post-vaccinal fibrosarcomas.** *J Vet Med A Physiol Pathol Clin Med* 2003; 50: 286–291.
- 7 Hendrick MJ and Brooks JJ. **Postvaccinal sarcomas in the cat: histology and immunohistochemistry.** *Vet Pathol* 1994; 31: 126–129.
- 8 Dubielzig RR, Hawkins KL and Miller PE. **Myofibroblastic sarcoma originating at the site of rabies vaccination in a cat.** *J Vet Diagn Invest* 1993; 5: 637–638.
- 9 Hirschberger J and Kessler M. **Das feline Fibrosarkom.** *Tierärztliche Praxis* 2001; 29: 66–71.
- 10 Doddy FD, Glickman LT, Glickman NW, et al. **Feline fibrosarcomas at vaccination sites and non-vaccination sites.** *J Comp Pathol* 1996; 114: 165–174.
- 11 Esplin DG, McGill LD, Meininger AC, et al. **Postvaccination sarcomas in cats.** *J Am Vet Med Assoc* 1993; 202: 1245–1247.
- 12 Madewell BR, Griffey SM, McEntee MC, et al. **Feline vaccine-associated fibrosarcoma: an ultrastructural study of 20 tumors (1996–1999).** *Vet Pathol* 2001; 38: 196–202.
- 13 Hendrick MJ, Shofer FS, Goldschmidt MH, et al. **Comparison of fibrosarcomas that developed at vaccination sites and at non-vaccination sites in cats: 239 cases (1991–1992).** *J Am Vet Med Assoc* 1994; 205: 1425–1429.
- 14 Couto CG and Macy DW. **Review of treatment options for vaccine-associated feline sarcoma.** *J Am Vet Med Assoc* 1998; 213: 1426–1427.
- 15 Hershey AE, Sorenmo KU, Hendrick MJ, et al. **Prognosis for presumed feline vaccine-associated sarcoma after excision: 61 cases (1986–1996).** *J Am Vet Med Assoc* 2000; 216: 58–61.
- 16 Kobayashi T, Hauck ML, Dodge R, et al. **Preoperative radiotherapy for vaccine associated sarcoma in 92 cats.** *Vet Radiol Ultrasound* 2002; 43: 473–479.
- 17 Sandler I, Teeger M and Best S. **Metastatic vaccine associated fibrosarcoma in a 10-year-old cat.** *Can Vet J* 1997; 38: 374.
- 18 Hendrick MJ, Goldschmidt MH, Shofer FS, et al. **Postvaccinal sarcomas in the cat: epidemiology and electron probe microanalytical identification of aluminum.** *Cancer Res* 1992; 52: 5391–5394.
- 19 Kass PH, Spangler WL, Hendrick MJ, et al. **Multicenter case-control study of risk factors associated with development of vaccine-associated sarcomas in cats.** *J Am Vet Med Assoc* 2003; 223: 1283–1292.
- 20 Macy DW. **The potential role and mechanisms of FeLV vaccine-induced neoplasms.** *Semin Vet Med Surg (Small Anim)* 1995; 10: 234–237.
- 21 Dean R, Adams V, Whitbread T, et al. **Study of feline injection site sarcomas.** *Vet Rec* 2006; 159: 641–642.
- 22 Gobar GM and Kass PH. **World Wide Web-based survey of vaccination practices, postvaccinal reactions, and vaccine site-associated sarcomas in cats.** *J Am Vet Med Assoc* 2002; 220: 1477–1482.
- 23 Coyne MJ, Reeves NC and Rosen DK. **Estimated prevalence of injection-site sarcomas in cats during 1992.** *J Am Vet Med Assoc* 1997; 210: 249–251.
- 24 Dean RS, Pfeiffer DU and Adams VJ. **The incidence of feline injection site sarcomas in the United Kingdom.** *BMC Vet Res* 2013; 9: 17.
- 25 Wilcock B, Wilcock A and Bottoms K. **Feline postvaccinal sarcoma: 20 years later.** *Can Vet J* 2012; 53: 430–434.
- 26 Deim Z, Palmai N and Cserni G. **Feline vaccine-associated fibrosarcoma induced by aluminium compound in two cats: short communication.** *Acta Vet Hung* 2008; 56: 111–116.
- 27 Kass PH, Spangler WL, Hendrick MJ, et al. **Multicenter case-control study of risk factors associated with development of vaccine-associated sarcomas in cats.** *J Am Vet Med Assoc* 2003; 223: 1283–1292.
- 28 Lester S, Clemett T and Burt A. **Vaccine site-associated sarcomas in cats: clinical experience and a laboratory review (1982–1993).** *J Am Anim Hosp Assoc* 1996; 32: 91–95.
- 29 Burton G and Mason KV. **Do postvaccinal sarcomas occur in Australian cats?** *Aust Vet J* 1997; 75: 102–106.
- 30 De Man MM and Ducatelle RV. **Bilateral subcutaneous fibrosarcomas in a cat following feline parvo-, herpes- and calicivirus vaccination.** *J Feline Med Surg* 2007; 9: 432–434.
- 31 Esplin DG, Bigelow M, McGill LD, et al. **Fibrosarcoma at the site of a lufenuron injection in a cat.** *Vet Cancer Soc Newsletter* 1999; 23: 8–9.
- 32 Gagnon A. **Drug injection-associated fibrosarcoma in a cat.** *Feline Pract* 2000; 28: 18–21.
- 33 Martano M, Morello E, Iussich S, et al. **A case of feline injection-site sarcoma at the site of cisplatin injections.** *J Feline Med Surg* 2012; 14: 751–754.
- 34 Munday JS, Banyay K, Aberdein D, et al. **Development of an injection site sarcoma shortly after meloxicam injection in an unvaccinated cat.** *J Feline Med Surg* 2011; 13: 988–991.
- 35 Srivastav A, Kass PH, McGill LD, et al. **Comparative vaccine-specific and other injectable-specific risks of injection-site sarcomas in cats.** *J Am Vet Med Assoc* 2012; 241: 595–602.
- 36 Buracco P, Martano M, Morello E, et al. **Vaccine-associated-like fibrosarcoma at the site of a deep nonabsorbable suture in a cat.** *Vet J* 2002; 163: 105–107.
- 37 Haddad JL, Goldschmidt MH and Patel RT. **Fibrosarcoma arising at the site of a retained surgical sponge in a cat.** *Vet Clin Pathol* 2010; 39: 241–246.
- 38 Daly MK, Saba CF, Crochik SS, et al. **Fibrosarcoma adjacent to the site of microchip implantation in a cat.** *J Feline Med Surg* 2008; 10: 202–205.
- 39 Carminato A, Vascellari M, Marchioro W, et al. **Microchip-associated fibrosarcoma in a cat.** *Vet Dermatol* 2011; 22: 565–569.
- 40 Hendrick MJ. **Feline vaccine-associated sarcomas: current studies on pathogenesis.** *J Am Vet Med Assoc* 1998; 213: 1425–1426.
- 41 Hendrick MJ. **Feline vaccine-associated sarcomas.** *Cancer Invest* 1999; 17: 273–277.
- 42 Nieto A, Sanchez MA, Martinez E, et al. **Immunohistochemical expression of p53, fibroblast growth factor-b, and transforming growth factor-alpha in feline vaccine-associated sarcomas.** *Vet Pathol* 2003; 40: 651–658.
- 43 Ellis JA, Jackson ML, Bartsch RC, et al. **Use of immunohisto-**

- chemistry and polymerase chain reaction for detection of oncornaviruses in formalin-fixed, paraffin-embedded fibrosarcomas from cats. *J Am Vet Med Assoc* 1996; 209: 767–771.
- 44 Kidney BA, Ellis JA, Haines DM, et al. Evaluation of formalin-fixed paraffin-embedded tissues obtained from vaccine site-associated sarcomas of cats for DNA of feline immunodeficiency virus. *Am J Vet Res* 2000; 61: 1037–1041.
- 45 Kidney BA, Haines DM, Ellis JA, et al. Evaluation of formalin-fixed paraffin-embedded tissues from vaccine site-associated sarcomas of cats for polyomavirus DNA and antigen. *Am J Vet Res* 2001; 62: 828–832.
- 46 Kidney BA, Haines DM, Ellis JA, et al. Evaluation of formalin-fixed paraffin-embedded tissues from vaccine site-associated sarcomas of cats for papillomavirus DNA and antigen. *Am J Vet Res* 2001; 62: 833–839.
- 47 Kidney BA, Haines DM, Ellis JA, et al. Evaluation of formalin-fixed paraffin-embedded tissues from feline vaccine site-associated sarcomas for feline foamy virus DNA. *Am J Vet Res* 2002; 63: 60–63.
- 48 Kalat M, Mayr B, Schleger W, et al. Chromosomal hyperdiploidy in a feline sarcoma. *Res Vet Sci* 1991; 51: 227–228.
- 49 Mayr B, Bockstahler B, Loupal G, et al. Cytogenetic variation between four cases of feline fibrosarcoma. *Res Vet Sci* 1996; 61: 268–270.
- 50 Mayr B, Eschborn U and Kalat M. Near triploidy in a feline fibrosarcoma. *Zentralbl Veterinarmed A* 1991; 38: 617–620.
- 51 Mayr B, Schaffner G, Kurzbauer R, et al. Mutations in tumour suppressor gene p53 in two feline fibrosarcomas. *Br Vet J* 1995; 151: 707–713.
- 52 Banerji N and Kanjilal S. Somatic alterations of the p53 tumor suppressor gene in vaccine-associated feline sarcoma. *Am J Vet Res* 2006; 67: 1766–1772.
- 53 Nambiar PR, Jackson ML, Ellis JA, et al. Immunohistochemical detection of tumor suppressor gene p53 protein in feline injection site-associated sarcomas. *Vet Pathol* 2001; 38: 236–238.
- 54 Nambiar PR, Haines DM, Ellis JA, et al. Mutational analysis of tumor suppressor gene p53 in feline vaccine site-associated sarcomas. *Am J Vet Res* 2000; 61: 1277–1281.
- 55 Mayr B, Reifinger M, Alton K, et al. Novel p53 tumour suppressor mutations in cases of spindle cell sarcoma, pleomorphic sarcoma and fibrosarcoma in cats. *Vet Res Commun* 1998; 22: 249–255.
- 56 Banerji N, Kapur V and Kanjilal S. Association of germ-line polymorphisms in the feline p53 gene with genetic predisposition to vaccine-associated feline sarcoma. *J Hered* 2007; 98: 421–427.
- 57 Mucha D, Laberke S, Meyer S, et al. Lack of association between p53 SNP and FISS in a cat population from Germany. *Vet Comp Oncol* 2014; 12: 130–137.
- 58 Hirschberger J. Principles of treatment for feline lymphoma. In: Ettinger SJ and Feldmann EC (eds). Textbook of veterinary internal medicine. 2nd ed. Philadelphia: WB Saunders, 2003, pp 98–102.
- 59 McEntee MC. The utility of contrast enhanced computed tomography in feline vaccine associated sarcomas: 35 cases. *Vet Radiol Ultrasound* 2000; 41: 575.
- 60 Martano M, Morello E and Buracco P. Feline injection-site sarcoma: past, present and future perspectives. *Vet J* 2011; 188: 136–141.
- 61 Phelps HA, Kuntz CA, Milner RJ, et al. Radical excision with five-centimeter margins for treatment of feline injection-site sarcomas: 91 cases (1998–2002). *J Am Vet Med Assoc* 2011; 239: 97–106.
- 62 Scherk MA, Ford RB, Gaskell RM, et al. 2013 AAEP Feline Vaccination Advisory Panel Report. *J Feline Med Surg* 2013; 15: 785–808.
- 63 Cronin K, Page RL, Spodnick G, et al. Radiation therapy and surgery for fibrosarcoma in 33 cats. *Vet Radiol Ultrasound* 1998; 39: 51–56.
- 64 McEntee MC and Page RL. Feline vaccine-associated sarcomas. *J Vet Intern Med* 2001; 15: 176–182.
- 65 Steger-Lieb A, Kostorz A, Hauser B, et al. Einsatz der Strahlentherapie beim vakzineassoziierten Sarkom der Katze, Erfahrungen aus 18 Fällen. *Tierärztliche Praxis* 2002; 30: 35–40.
- 66 Martano M, Morello E, Ughetto M, et al. Surgery alone versus surgery and doxorubicin for the treatment of feline injection-site sarcomas: a report on 69 cases. *Vet J* 2005; 170: 84–90.
- 67 Bray J and Polton G. Neoadjuvant and adjuvant chemotherapy combined with anatomical resection of feline injection-site sarcoma: results in 21 cats. *Vet Comp Oncol*. Epub ahead of print 7 February 2014. DOI 10.1111/vco.12083.
- 68 Jahnke A, Hirschberger J, Fischer C, et al. Intra-tumoral gene delivery of feIL-2, feIFN-gamma and feGM-CSF using magnetofection as a neoadjuvant treatment option for feline fibrosarcomas: a phase-I study. *J Vet Med A Physiol Pathol Clin Med* 2007; 54: 599–606.
- 69 Huttlinger C, Hirschberger J, Jahnke A, et al. Neoadjuvant gene delivery of feline granulocyte-macrophage colony-stimulating factor using magnetofection for the treatment of feline fibrosarcomas: a phase I trial. *J Gene Med* 2008; 10: 655–667.
- 70 Jas D, Soyer C, De Fornel-Thibaud P, et al. Adjuvant immunotherapy of feline injection-site sarcomas with the recombinant canarypox virus expressing feline interleukine-2 evaluated in a controlled monocentric clinical trial when used in association with surgery and brachytherapy. *Trials Vaccinol* 2015; 4: 1–8.
- 71 Quintin-Colonna F, Devauchelle P, Fradelizi D, et al. Gene therapy of spontaneous canine melanoma and feline fibrosarcoma by intratumoral administration of histoincompatible cells expressing human interleukin-2. *Gene Ther* 1996; 3: 1104–1112.
- 72 VAFSTF. Vaccine-Associated Feline Sarcoma Task Force guidelines. Diagnosis and treatment of suspected sarcomas. *J Am Vet Med Assoc* 1999; 214: 1745.
- 73 Shaw SC, Kent MS, Gordon IK, et al. Temporal changes in characteristics of injection-site sarcomas in cats: 392 cases (1990–2006). *J Am Vet Med Assoc* 2009; 234: 376–380.
- 74 Haas J. Klinik, Labordiagnostik und verwendete Impfstoffe bei Katzen mit einem Fibrosarkom: eine Übersicht über die Patienten der Medizinischen Kleintierklinik 1999–2007. Munich: Ludwig Maximilians University; 2009.
- 75 Richards JR, Elston TH, Ford RB, et al. The 2006 American Association of Feline Practitioners Feline Vaccine Advisory Panel report. *J Am Vet Med Assoc* 2006; 229: 1405–1441.
- 76 Hendricks CG, Levy JK, Tucker SJ, et al. Tail vaccination in cats: a pilot study. *J Feline Med Surg* 2014; 16: 275–280.
- 77 Devauchelle P and Magnol JP. Dynamique de la réaction inflammatoire induite chez le chat par l'administration sous-cutanée d'un vaccin non adjuvé. Proceedings of the CNVSPA Congress; 2001; Lille, France.
- 78 Macy DW and Chretien J. Local postvaccinal reactions of a recombinant rabies vaccine. Proceedings of the 1999 Vet Forum, pp 44–49.
- 79 Day MJ, Schoon HA, Magnol JP, et al. A kinetic study of histopathological changes in the subcutis of cats injected with non-adjuvanted and adjuvanted multi-component vaccines. *Vaccine* 2007; 25: 4073–4084.